



CASE REPORT

OSTEOSARCOMA OF THE MANDIBLE DEVELOPED AFTER TOOTH EXTRACTION TREATED WITH SURGERY- A CASE REPORT

Arun Kumar Shah^{1*}, Nabeela Riaz¹, Deepak Thakurathi¹, Ahmad Liaquat¹

¹Department of Oral and Maxillofacial Surgery, King Edward Medical University.

Received: 25th May 2019

Accepted: 23 June, 2019

Published: 17 Sept, 2019

Key words: Osteosarcoma; Sunburst appearance; Tooth extraction; Technetium⁹⁹.

**Correspondence to:* Arun Kumar Shah, Department of Oral and Maxillofacial Surgery, King Edward Medical University, Lahore, Pakistan.
Email: dr.arunshah@hotmail.com

DOI:<https://doi.org/10.3126/jcmc.v9i3.25792>

Citation

Shah AK, Riaz N, Thakurathi D, Liaquat A. Osteosarcoma of the mandible developed after tooth extraction treated with surgery- a case report. Journal of Chitwan Medical College. 2019; 9(29):100-03.



ABSTRACT

Osteosarcoma of jaw is a rare malignant condition of osteoid tissue with same histopathological features but different biological behaviour compared to long bone. It has characteristic clinical, radiographic and histopathologic features and treatment after early diagnosis followed by surgery (with negative margin) combined with chemotherapy or radiotherapy has better prognosis and survival rate. Here we report the case of osteosarcoma of mandible after tooth extraction in a 55-year-old female and treated by surgery.

INTRODUCTION

Osteosarcoma is an aggressive, most common malignant neoplasm of mesenchymal origin characterized by the formation of osteoid tissue by sarcomatous stroma.^{1,2} It mainly affects long bone and is rare in jaw (about 5% to 13%) with more mandibular involvement than in maxilla.³ It usually occurs in the third and fourth decades of life with more male predilection. The posterior body and ramus in mandible whereas alveolar ridge, sinus floor and palate in maxilla are mainly involved.⁴

Patient usually presents with the common symp-

toms of swelling of the bone and pain of variable intensity. Loosening of teeth, paresthesia, nasal obstruction (in case of maxillary tumor), lack of healing and swelling at the site of the tooth extraction and trismus are also noted.⁵ Rarely lung metastasis is seen.⁶

The differential diagnosis for the osteosarcoma includes inflammatory (osteomyelitis), odontogenic (keratocystic odontogenic tumor), osteogenic (chondrosarcoma, Ewing sarcoma), non-odontogenic, nonosteogenic (fibrous dysplasia).⁶

Radiologically osteosarcoma presents as three characteristic appearances, radiolucent (characterized by a total absence of bone formation within the tumour), mixed (with mottled appearance with small areas of amorphous ossification separated by non-ossified tumour tissue) and radio-opaque (with lamellar ossification characterized by bony plates irradiating from a focus like a 'sunburst'), in all types peripheral borders are ill defined and irregular with resorbed root of involved tooth. There is periodontal ligament widening with the presence of Codman's triangle.^{7,8}

Histologically, Osteosarcoma is classified into three subtypes: osteoblastic, chondroblastic, fibroblastic depending upon the type of extracellular matrix produced by the stroma.⁹

Bone sarcoma has been staged by American Joint Committee on Cancer (AJCC) on basis of TNM staging where, 'T' represents size of tumor, 'N' represents regional lymph node involvement, 'M' represents distant metastasis and 'G' represents histopathologic grade also by Enneking surgical staging system depends upon grade and site of tumour.¹⁰

Out of the multimodal treatments, aggressive surgical resection with negative margins and reconstructive techniques remain the primary modality, although chemotherapy using multiple agents and preoperative chemotherapy along with radiotherapy has also been advocated. The overall survival rate is 40-50% and the better prognosis depended upon early diagnosis, wide excision with negative surgical margin and a low grade tumor.¹¹

The osteosarcoma of jaw unlike other bone tumor is rare and is biologically different and histopathologically similar with osteosarcoma of long bone, so few case reports and studies are available. In jaw, sarcoma arising after extraction from extraction site is rarely reported. In this article a case of osteosarcoma has been reported that developed after extraction of tooth in mandible.

CASE REPORT

A 55-year-old female presented to OPD of Oral and Maxillofacial Surgery, Mayo hospital, Lahore with a chief complaint of swelling in jaw for 4 months. The dental history revealed extraction of right 1st molar 5 months ago. According to patient, she was

apparently well 5 months ago then she experienced toothache on right side of lower jaw for which she had extraction of 1st molar by local dentist. After 4 months she discovered a soft tissue growth in extraction site. The swelling was slowly growing and painful leading to difficulty in chewing and swallowing. It continued to increase up to the presenting state. History and clinical examination and radiological examination were done. Incisional biopsy from growth revealed as the case of osteosarcoma of mandible for which she was admitted for surgical treatment.

The patient was thin built, sitting comfortably in bed and was well oriented to time, place and person. Her all vital parameters were in normal range. On clinical examination, The swelling was located on mandible measuring 6x4 cm in size with multiple nodules extending from left 2nd premolar to right side retromolar region, skin overlying the swelling was erythematous (Figure 1). There was no tenderness with normal temperature and texture. The lesion was firm to hard in consistency with irregular margin and multiple breaches in mucosa with obliteration of labial and lingual vestibule. Tongue movements were normal with paraesthesia of lip on the right side was noted. There was no cervical lymphadenopathy with adequate mouth opening and TMJ movements were palpable.

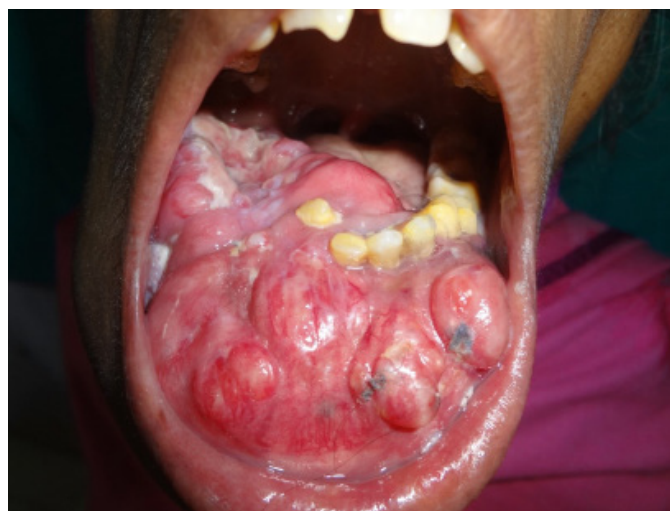

Figure 1: Picture showing intraoral view of osteosarcoma

The radiographic evaluation included orthopantomogram (OPG), bone scan and x-ray chest p/a view. OPG of the mandible showed area of heterogeneous opacities with ill-defined margin and characteristic sun-ray appearance with displacement

of left 2nd premolar and was edentulous with only 2nd premolar and first molar on right side (Figure 2). Bone scan shows abnormally increased uptake of radionuclide in lower jaw region and focal area of abnormal increased uptake of radionuclide in right femur (Figure 3).

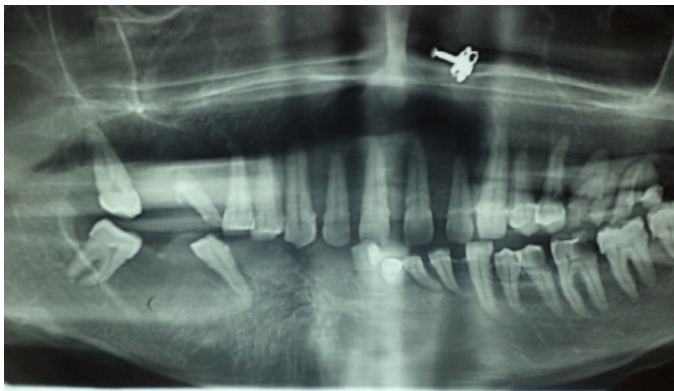

Figure 2: showing sunburst appearance of the right jaw adjacent to the first premolar

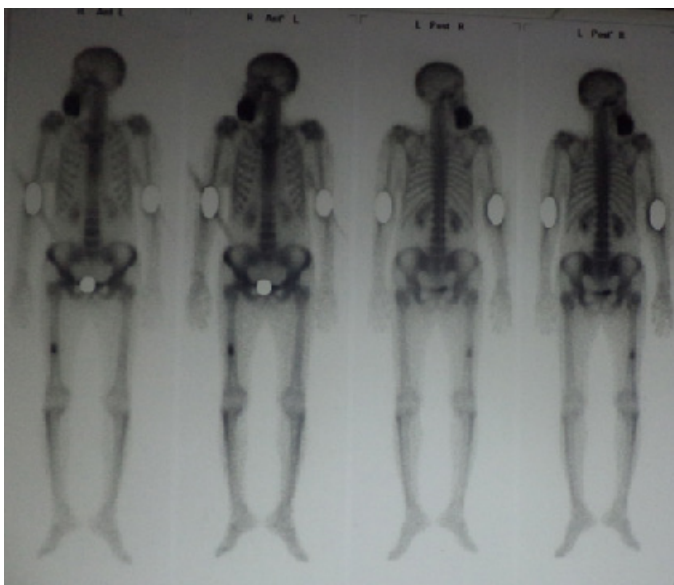


Figure 3: Picture showing bone scan with increased uptake of technetium in lower jaw and right femur

Other routine investigations such as complete blood count, prothrombin time, activated partial thromboplastin time, viral screening were also done which were within normal limit. An incisional biopsy revealed malignant neoplasm of cells and hyperchromatic, pleomorphic nuclei. Osteoid formation by malignant cells along with areas of mitosis and myxoid at places were also seen. These histological features were suggestive of osteosarcoma of the mandible.

Enneking Staging I- low grade lesion (low histological

grade), intra compartmental anatomic location of the tumour was diagnosed and treatment plan was established.

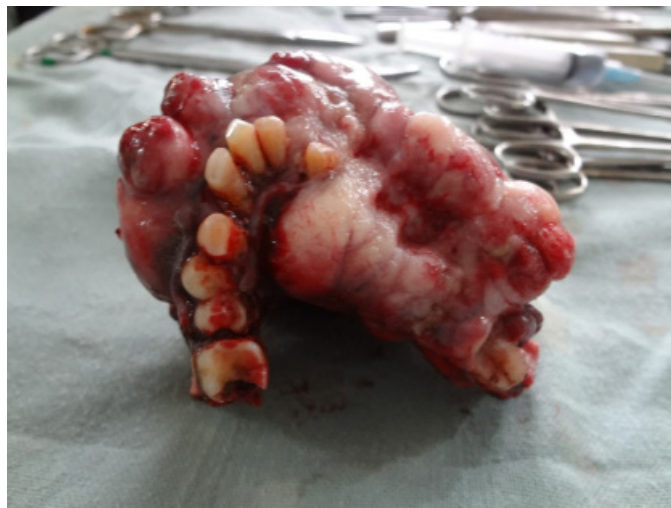

Figure 4: Tumour after resection

After proper counselling and taking informed written consent resection of tumour from right side of body to the left side of body of mandible distal to left first molar with 1.5 cm of clinical healthy margin (Figure 4). Remaining mandible was stabilized by reconstruction plate. Post-operative period was uneventful. After 2 weeks, the patient was referred to department of oncology for adjuvant chemotherapy.

The prognosis and outcome of the patient was good with period of disease free survival till date and reduced symptoms and functional debility with 3 monthly follow up.

DISCUSSION

Primary bone cancers are extremely rare neoplasm, accounting for less than 0.2% of all cancers. Osteosarcoma (35%), chondrosarcoma (30%) and Ewing's sarcoma (16%) are the three most common forms of bone sarcoma.

Osteosarcoma arise from different clinical settings as Paget's disease, fibrous dysplasia, giant cell tumour, multiple osteochondromas, bone infarct, chronic osteomyelitis and osteogenesis imperfecta. There is mutation or amplification of one or more genes pathways including Rb, p53, RECQ helicase, SAS (sarcoma amplified sequence) and telomere fidelity.¹¹ In this case, it was aggravated by the tooth extraction.

The males with 3rd to 4th decade are more commonly involved but in our case it was female of 55years. Clinical characteristic of the case report was in agreement with the previous literature and included swelling, paraesthesia of lip, erythematous multiple ulcerated nodules.¹ The pain in our case was mild and insignificant.

There was mixed radiolucent- radiopaque lesion with marked sunburst appearance in OPG. The metastasis for the osteosarcoma is mainly seen in lungs and liver,² but in our case, bone scan was relevant with significant uptake in jaw and right femur.

The confirmatory diagnosis was done by incisional biopsy, but other investigations like PET couldn't be done because of the patient financial condition. Histopathologic report revealed osteoblastic type having hyperchromatic, pleomorphic nuclei and osteoid formation by malignant cells with myxoid and mitosis was also seen.

In this case, resection of tumor with safe margin from right side of body of mandible and left side of body of mandible distal to left first molar. Although there are options of preoperative chemotherapy but surgical treatment was carried out first and patient was sent for adjuvant chemotherapy.

CONCLUSION

Pain is important clinical presentation of osteosarcoma but pain in case of the present patient was insignificant. The tooth extraction is one of the predisposing factors for the development of osteosarcoma of jaw, so proper extraction technique, post-operative care and medication along with regular follow up should be done. Swelling of the bone along with ulcerated multiple nodules should be properly investigated and treated to avoid further complications.

REFERENCES

1. Ottaviani, Giulia, and Norman Jaffe. "The epidemiology of osteosarcoma." *Pediatric and Adolescent Osteosarcoma*. Springer US, 2010. 3-13.
2. Booth, Peter Ward, Stephen A. Schendel, and Jarg-Erich Hausamen, eds. *Maxillofacial surgery*.

Vol. 1. Churchill Livingstone, 1999. Booth, Peter Ward, Stephen Schendel, and Jarg-Erich Hausamen. *Maxillofacial surgery*. Vol. 2. Churchill Livingstone, 2007.

3. Khorate MM, Goel S, Singh MP, Ahmed J. Osteosarcoma of mandible: a case report and review of literature. *J Cancer Sci Ther*.2010;2(4):122-5. [\[PDF\]](#)
4. Mardinger O, Givol N, Talmi YP, Taicher S. Osteosarcoma of the jaw: the Chaim Sheba Medical Center experience. *Oral Surgery, Oral Medicine, Oral Pathology, Oral Radiology, and Endodontology*. 2001 Apr 1;91(4):445-51. [\[DOI\]](#)
5. Bojan A, Christy W, Chanmougananda S, Ashokan K. Osteosarcoma of mandible: A case report and review of literature. *J Clin Diagn Res*. 2012;6(4):753-7.[\[PDF\]](#)
6. Laskar S, Basu A, Muckaden MA, D'Cruz A, Pai S, Jambhekar N, Tike P, Shrivastava SK. Osteosarcoma of the head and neck region: lessons learned from a single-institution experience of 50 patients. *Head & Neck: Journal for the Sciences and Specialties of the Head and Neck*. 2008 Aug;30(8):1020-6. [\[DOI\]](#)
7. Bianchi SD, Boccardi A. Radiological aspects of osteosarcoma of the jaws. *Dentomaxillofacial Radiology*. 1999 Jan;28(1):42-7. [\[DOI\]](#)
8. Neville B. W., Damm D. D., Allen C. M, Bowquot J. E., *oral and maxillofacial pathology*, 3rd edition, elseviers, 2010.
9. Shetty DC, Ahuja P, Urs AB, Kaur R. Histopathological variants of jaw osteosarcoma. *Int J Pathol*. 2009;7(2):98-101. [\[PDF\]](#)
10. NCCN guidelines for bone cancer 2011
11. König M, Mork J, Hall KS, Osnes T, Meling TR. Multimodal treatment of osteogenic sarcoma of the jaw. *Skull Base*. 2010 May;20(03):207-12. [\[DOI\]](#)